M.H.Antikchi

Gastroenterologist & Hepatologist

Islamic Azad university

Yazd, Iran

CASE:

- A 37 year old woman known case of SLE admitted to the hospital for evaluation of anorexia, abdominal pain, weight loss and occasional fever.
- She had generalized abdominal pain with preference in RLQ since 5months ago and she had weight loss about 4kg at this period.
- She was from a village of zabol city and SLE disease diagnosed for his three years ago with presentation of malar rash, hair loss, arthritis, leukopenia, proteinuria, positive ANA and anti dsDNA.
- At present, she was on low dose prednisolone (5mg daily), Cellcept (1gr D) and HCQ 200mg daily.

PH.EX

- The patient was malnourished.
- BP: 108/75 PR:74 RR: 12 T:37.8C
- Head and neck: pale conjunctiva, No malar rash
- Hear: Normal S1, S2
- Lung: Clear
- Abdomen: Soft, Mild Ascites, Generalized tenderness (preference in RLQ)
- Musculoskeletal: No arthritis

LAB DATA:

- WBC: 5300, PMN 48%, Lymph 51%, Eos 1%
- RBC: 3.9 $x10^6$
- Hb: 10.7
- MCV: 84
- PLT: 153,000
- BUN: 25
- Cr: 1.1
- ESR: 94
- CRP: 8

ANA: (+)

Anti dsDNA: (-)

C3,C4: Normal

AST: 33

ALT: 34

ALP: 286

24 urine protein: 230mg

Lipase: 34

CASE CONT,

- **Abdominal and pelvic sonogeraphy & CT scan:**
  - Concentric mural thickening in the ileocecal region
  - Asymmetric thickening of the medial cecal wall
  - Several mesenteric lymph nodes
  - Mild to moderate ascites

CASE CONT,

- **Ascetic fluid analysis:**
- Albumin: 2.8
- Total protein: 4.3
- WBC: 680 (lymph 80%)
- LDH:375
- Serum albumin: 3.4
- AFB smear: Negative
- Mycobacterial culture: Negative

Case cont,

- Colonoscopy:

- Circumferential ulcers involving the cecum and ileocecal valve
- Cecal peudopolyps
- Patulous ileocecal valve



Multiple deep biopsies were taken

and sent for AFB-PCR and histopathology

INTRODUCTION:

- 40%–60% of SLE patients have gastrointestinal (GI) involvement.
- SLE can affect any part of the GI tract, from the mouth to the anus.
- GI manifestations can be caused by:
    - SLE
    - Medication-related side effects
    - Non-SLE causes including infection, Chroh,s disease, Malignancy(Lymphoma)

SYSTEMIC LUPUS ERYTHEMATOSUS & ABDOMINAL PAIN

- **Abdominal pain** is a common finding in patients with systemic lupus erythematosus (SLE), occurring in as many as half of all SLE:
  - Peritonitis from polyserositis,
  - Dyspepsia from reflux, nausea and vomiting
  - **Enteritis**
  - Ascites
  - Mesenteric ischemia
  - Pancreatitis (vasculitis, antiphospholipid associated thrombosis, hypertriglycerimia, AZT use)
  - Pneumatosis intestinalis from necrotizing enterocolitis
  - Hepatobiliary abnormalities (acute acalculous cholecystitis,…)

NON-SLE CAUSES ENTERITIS:

- Crohn's disease (prevalence: 0.3% to 0.7%)
- Intestinal TB
- Bacterial infection
- Vasculitis
- Ischemia
- Neoplasms
- Medication-induced or eosinophilic enteritis.

DEEP BIOPSIES HISTOPATHOLOGY

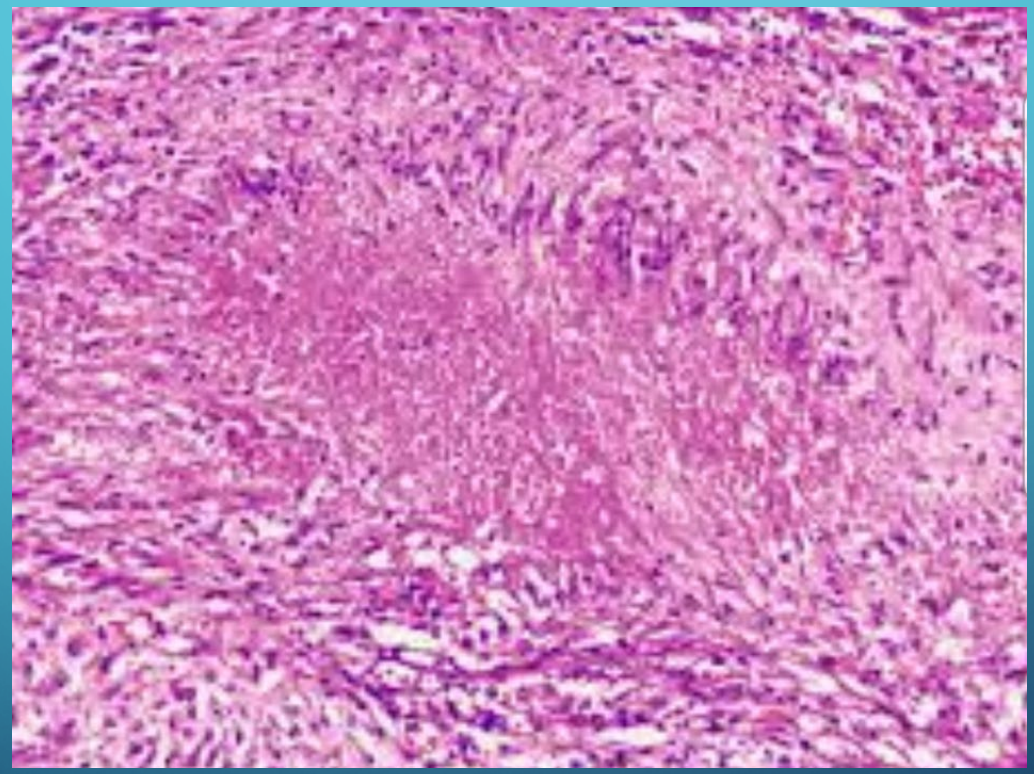

DIAGNOSIS

Ileocolitis Tuberculosis

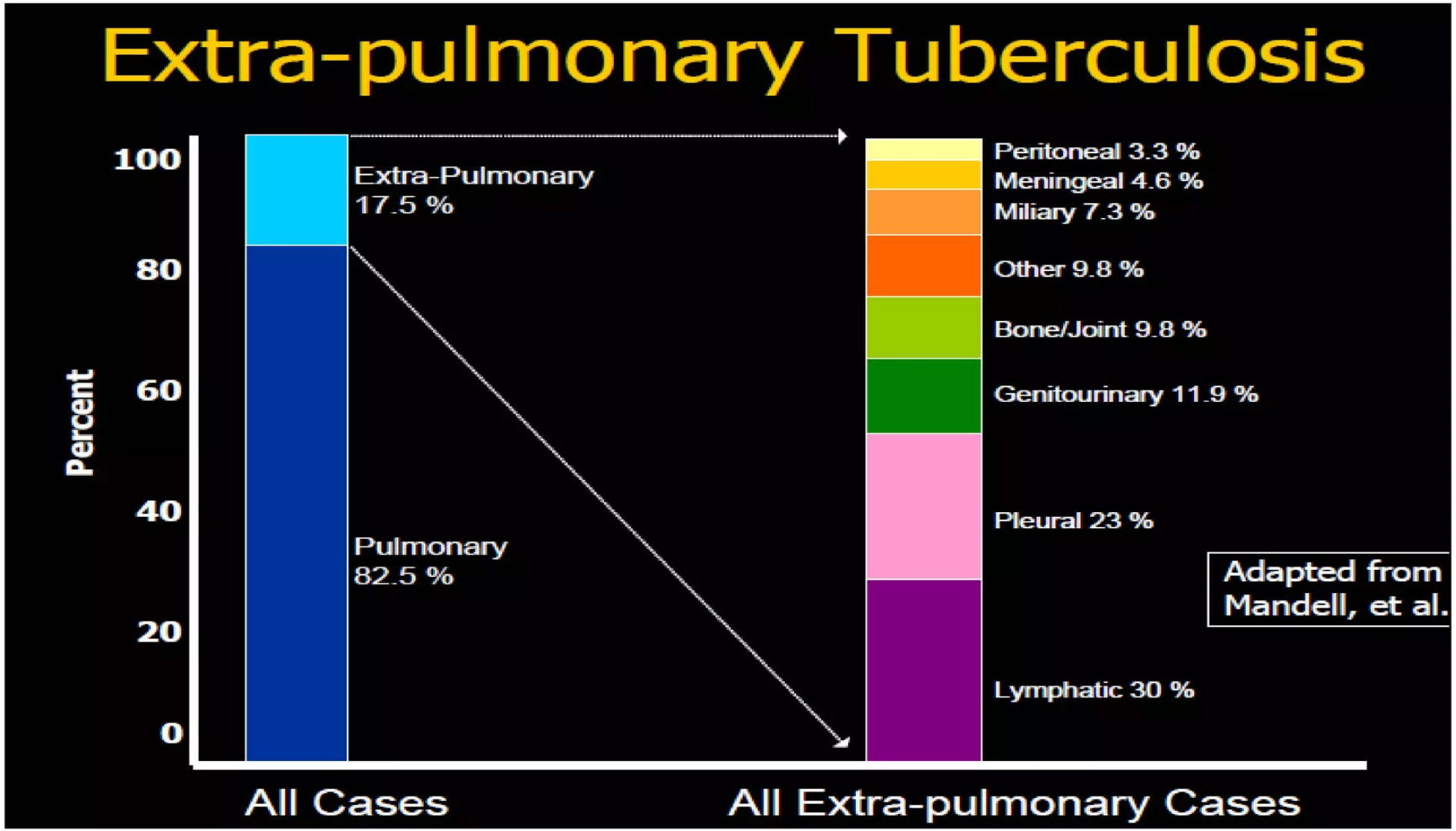
Extra-pulmonary Tuberculosis
Percent
100
80
60
40
20
0
Extra-Pulmonary
17.5 %
Pulmonary
82.5 %
Peritoneal 3.3 %
Meningeal 4.6 %
Miliary 7.3 %
Other 9.8 %
Bone/Joint 9.8 %
Genitourinary 11.9 %
Pleural 23 %
Lymphatic 30 %
Adapted from Mandell, et al.
All Cases
All Extra-pulmonary Cases

ABDOMINAL TUBERCULOSIS

- Peritoneal Tuberculosis
- Intestinal Tuberculosis
- Less frequent forms are esophageal, gastroduodenal, pancreatic, hepatic, gallbladder and biliary tuberculosis

DIFFERENT CLINICAL PRESENTATION OF ABDOMINAL TUBERCULOSIS

- Clinical presentation may be:
  - Acute
  - Acute on Chronic
  - Chronic
- common in 25-50 years age group
- Equal in both sex

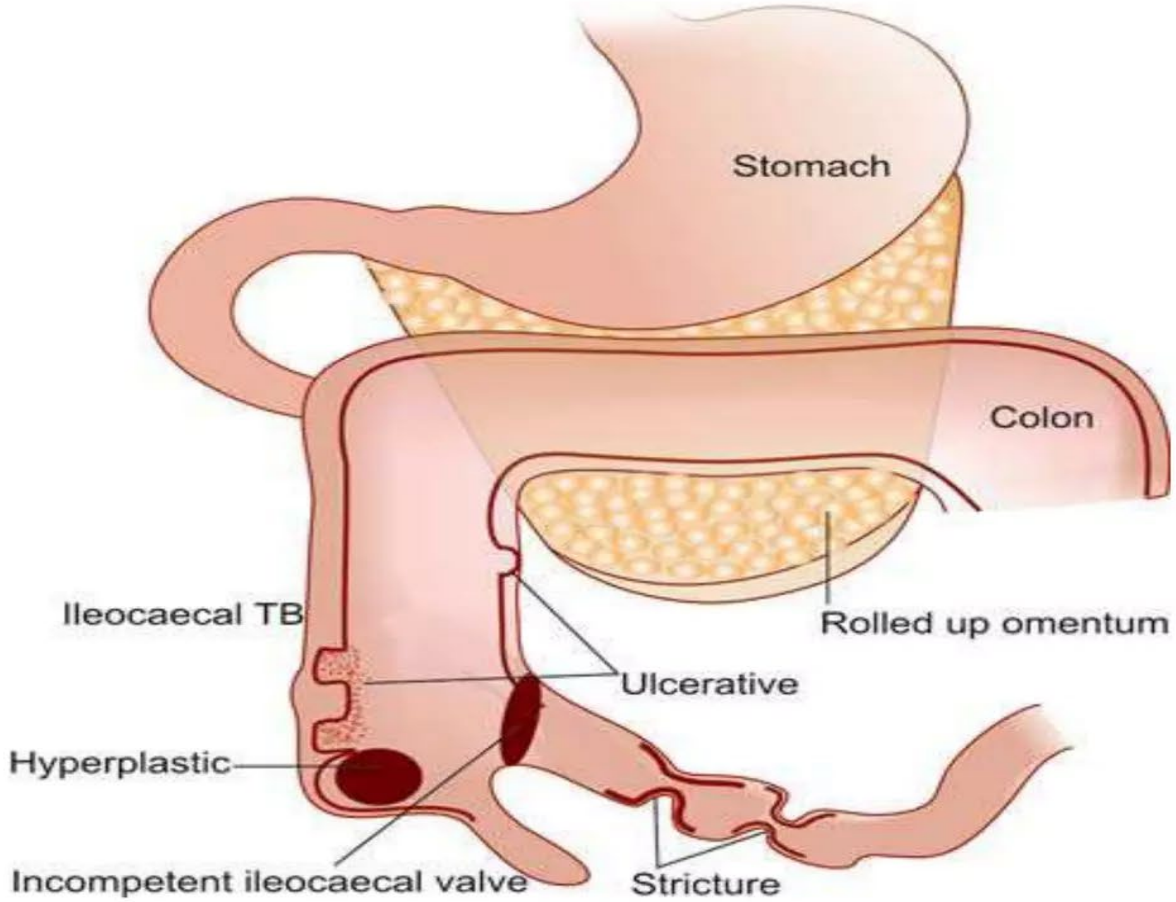
Stomach
Colon
Ileocaecal TB
Rolled up omentum
Ulcerative
Hyperplastic
Incompetent ileocaecal valve
Stricture

TYPE OF ABDOMINAL TUBERCULOSIS

Types:

- *Ulcerative—diarrhoea and malabsorption*
- *Stricture—subacute or acute intestinal obstruction*
- *Hyperplastic—mass abdomen (RIF) and obstruction*
- *Ascites—generalised distension of abdomen*
- *Localised* -- intra-abdominal mass, which may mimic ovarian cyst, retroperitoneal cyst or mesenteric cyst.
- *Peritoneal—abdominal cocoon; vague abdominal pain,*
- parietal peritoneal thickening as doughy abdomen; mass abdomen
- *Mesenteric—tabes mesenterica, obstruction, mass*
- Associated tuberculosis of other organs is seen in 30% of cases

ABDOMINAL TUBERCULOSIS CLINICAL MANIFESTATION

- **Tuberculous peritonitis:**
  - Abdominal pain (65%)
  - Fever (59%)
  - Weight loss (61%)
  - Diarrhea (21%)
  - Constipation (11%)
  - Ascites (73%)
  - Abdominal tenderness
  - Hepatomegaly (28%) Splenomegaly (14%)
  - Cnstitutional symptoms occur in half of the patients

ABDOMINAL TUBERCULOSIS CLINICAL MANIFESTATION

- **Intestinal Tuberculosis :**
  - Abdominal pain (30% to 88%)
  - Fever (21% to 73%)
  - Diarrhea (5% to 47%
  - loss of appetite (30% to 90%)
  - loss of weight (8% to 80%)
  - Constipation (7% to 24%)
  - Hematochezia (5% to 15%).

INTESTINAL TUBERCULOSIS

- Intestinal tuberculosis is an uncommon clinical manifestation of tuberculosis, representing approximately 5% of extra-pulmonary cases reported in the US
- Possible pathophysiology includes :
  - Swallowing of sputum with direct seeding
  - Hematogenous spread
  - Ingestion of milk from cows affected by bovine TB

INTESTINAL TUBERCULOSIS

- The most commonly affected parts of the intestine are the terminal ileum and cecum.
- Typical manifestations are abdominal pain, intestinal swelling, intestinal obstruction, hematochezia, a palpable abdominal mass, fever, weight loss, and night sweats
- The differentiation between Crohn's disease (CD) and intestinal tuberculosis would be difficult

INTESTINAL TUBERCULOSIS

- Differential points are the presence of ascites, both-sides of ileocecal valve involvement leading to incompetence, submucosal large caseation granuloma, all of which are uncommon in CD
- Identifying TB in a timely manner is crucial because of its high mortality, ranging from 8% to 50% in many studies.
- Factors related to poor prognosis in intestinal TB include the patient's age, pre-existing liver cirrhosis, and delay in initiating anti-tuberculosis treatment

INTESTINAL TUBERCULOSIS

- Peritoneal carcinomatosis closely mimics peritoneal tuberculosis, while Crohn's disease closely mimics intestinal tuberculosis.
- Imaging modalities (ultrasound, computed tomography, magnetic resonance imaging and occasionally positron emission tomography) guide the line of evaluation

ASCITES & ABDOMINAL TUBERCULOSIS

- Typically, tubercular ascites is a low-serum ascites albumin gradient (SAAG) and high-protein ascites with a predominance of lymphocytes.
- This typical pattern may not be seen in patients with chronic liver disease (high SAAG), or malnutrition (low protein).
- Ascitic fluid cytology for peritoneal carcinomatosis

ASCITES FLUID IN ABDOMINAL TUBERCULOSIS

Ascitic fluid in abdominal tuberculosis

- Exudate with protein level > 2.5 g/dl
- Serum-ascitic fluid albumin gradient is < 1.1
- Lymphocyte predominant cells with count as high as 4000/mm3 >250/cumm
- AFB in ascitic fluid is seen only < 3% cases
- ADA (Adenosine deaminase activity) in ascitic fluid (95% specificity and 98% sensitivity)
- Specific gravity >1.016
- Glucose < 30 mg
- Decreased pH
- LDH more than 90 units/litre

ASCITES ADA & ABDOMINAL TB

- Adenosine deaminase (ADA) in peritoneal fluid offers a feasible, sensitive and highly specific test for **peritoneal Tuberculosis.**
- INDEX TB Guidelines suggest that a cut-off of 39 U/L be used for the diagnosis.
- False positives could occur in peritoneal carcinomatosis, lymphoma, hemorrhagic ascites and pus, while false negatives could occur in early stages or underlying cirrhosis

MICROBIOLOGICAL TESTS ON ASCITES FLUID & ABDOMINAL TB

- The yield of acid-fast bacilli (AFB) smear testing is extremely poor with a sensitivity of < 5%
- Mycobacterial culture has a sensitivity of around 35%, but would be specific if positive
- There is a growing interest in PCR-based diagnostics, especially those which are available as point-of-care tools.

IMAGING & ABDOMINAL TUBERCULOSIS

- Abdominal ultrasound (USG) :
  - Evaluation of lymphadenopathy, peritoneal or omental thickening, ascites, mesenteric changes and bowel wall thickening.
  - Provide material for microbiological, cytological or histopathological evaluation
  - Negative ultrasound should not be used to exclude abdominal TB in HIV-positive individuals

IMAGING & ABDOMINAL TUBERCULOSIS

- Computed tomography (CT) has emerged as an excellent tool for evaluating abdominal diseases :
  - It provides good visualization of both luminal and extraluminal findings
  - Concomitant genitourinary involvement, especially in females with salpingitis, hydrosalpinx, adnexal lesions and tubo-ovarian masses, could suggest underlying TB

RADIOGRAPHY & ABDOMINAL TUBERCULOSIS

Investigations

1. Chest Xray – for primary focus
2. Blood investgations: Mantoux, ELISA, serum IgG
3. ESR- raised
4. Plain X-ray abdomen
    I. Intestinal obstruction
    II. Calcified lymph nodes
    III. Hollow viscous perforation
    IV. Calcified Granuloma in liver





VISUAL APPEARANCE & ABDOMINAL TB

- Colonoscopy
  - Findings Because the ileocecal region and the ascending colon are the most frequent sites of involvement in GITB, ileocolonoscopy is an important tool in diagnosing GITB.
  - While the presence of transverse ulcers (sensitivity: 43% and specificity: 88%) and a patulous ileocecal valve (sensitivity: 38% and specificity: 91%) was suggestive of GITB, the presence of aphthous ulcers, cobblestone appearance, skip lesions and longitudinal ulcers was more suggestive of CD

COLONOSCOPY & ABDOMINAL TB

Colonoscopy

- To rule out carcinoma
- Shows mucosal nodules, ulcers, strictures, deformed ileocaecal valve, mucosal oedema and diffuse colitis
- Biopsy can be taken to eslablish the diagnosis

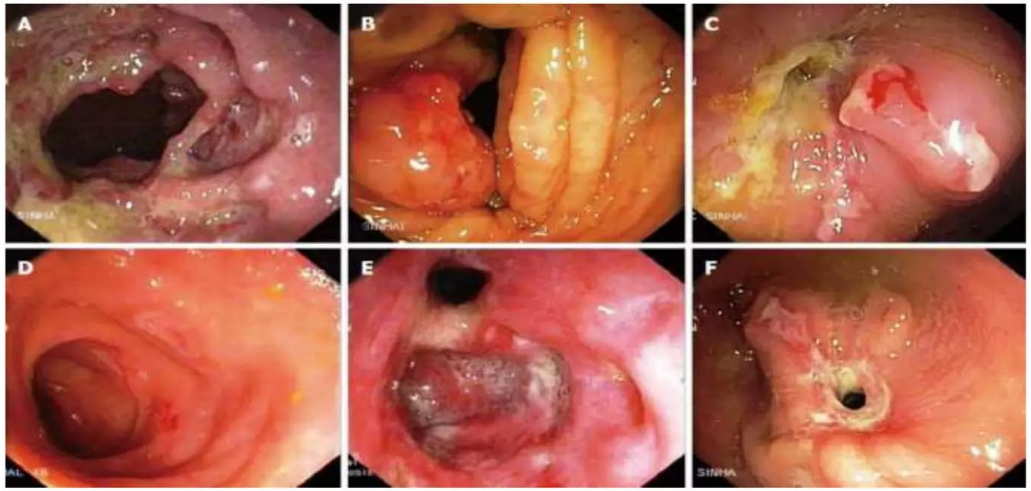

Capsule endoscopy is also useful to see small intestinal (tuberculous) pathology in difficult cases. Can cause obstrction at stricture site.



INTESTINAL BIOPSY-BASED TESTS & ABDOMINAL TB

- Microbiology The diagnosis of ITB often relies on testing of the intestinal tissue. It is important to obtain adequate tissue samples for evaluation. (ICMR) suggested that at **least six biopsy** pieces be obtained in sterile saline for microbiological testing

- **Microbiological positivity is the gold standard for the diagnosis of GITB.** The tissue obtained by surgery/colonoscopy should be subjected to microbiological testing.

INTESTINAL BIOPSY-BASED TESTS & ABDOMINAL TB

- Although AFB staining is extremely important for pulmonary samples, the positivity rates are extremely low for GITB. TB culture provides an important tool for the diagnosis of GITB and also helps in testing for drug sensitivity in appropriate clinical settings.

- Culture positivity has been reported to vary from 7% to 79%, but is usually less than 50%

RECENT SEROLOGICAL TEST

- Interferon-gamma release assays (IGRAs) have emerged as an important tool for the diagnosis of latent TB infection. These have also been used for possible discrimination of abdominal TB from mimics like Crohn's disease or other causes of ascites.

- PCR Test (more sensitive and specific than AFB smear and culture and results are available sooner)

VISUAL APPEARANCE & ABDOMINAL TB

- Laparoscopy
  - peritoneal biopsy is a tool for rapid and accurate diagnosis of TBP.
  - Not commonly performed due to the invasive nature of the procedure, complications such as bowel perforation and bleeding and lack of availability at peripheral setups.

DIFFERENTIAL DIAGNOSIS OF ABDOMINAL TUBERCULOSIS

Tuberculosis	Crohn's Disease
• Mural thickening without stratification. • Strictures concentric. • Fibrofatty proliferation of mesentary very rare. • No vascular engorgement in mesentary. • High dense ascitis.	• Mural thickening with stratification. • Strictures eccentric. • Fibrofatty proliferation of mesentary. • Hypervascular mesentary. • Abscesses.

COMPLICATIONS OF ABDOMINAL TUBERCULOSIS

- Obstruction 20%
- Malabsorption-Blind loop syndrome
- Dissemination of TB
- Fistulae
- Cold abscess formation
- Perforation & Hemorrhage (Rare)

TREATMENT OF ABDOMINAL TUBERCULOSIS

- Medical
  - First line of management
  - Anti- Tuberculosis Therapy
- Surgery

Medical management[2]

DRUG	DOSAGE (mg/kg)	ADVERSE EFFECTS
ISONIAZID	5	PERIPHERAL NEURITIS, hepatitis, fever, rashes, acne.
RIFAMPACIN	10	HEPATITIS, orange urine, skin rashes, 'flu syndrome', purpura
ETHAMBUTOL	15	OPTIC NEURITIS,hyperurecemia
PYRAZINAMIDE	25	Hepatotoxicity, hyperurecemia, arthralgia, rashes.
STREPTOMYCIN	15	OTOTOXICITY, NEPHROTOXICITY

-WHO recommends 6-9 months course

-Commonly patient presents with complications and late presentations are also common in many. So, more often treatment for one year may be required in these patients.

Indications for steroids in tuberculosis

- Miliary tuberculosis
- Tuberculous meningitis
- Adrenal tuberculosis
- Tuberculous pericarditis
- Pleural and endobronchial tuberculosis
- In abdominal tuberculosis to prevent adhesions
- Tuberculosis of the mediastinal lymph nodes (Rapidly
- progressive)
- Genitourinary tuberculosis
- Ocular tuberculosis

SURGICAL TREATMENT

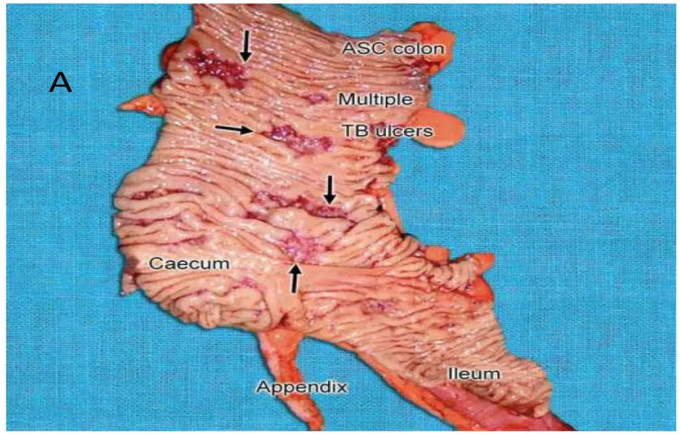

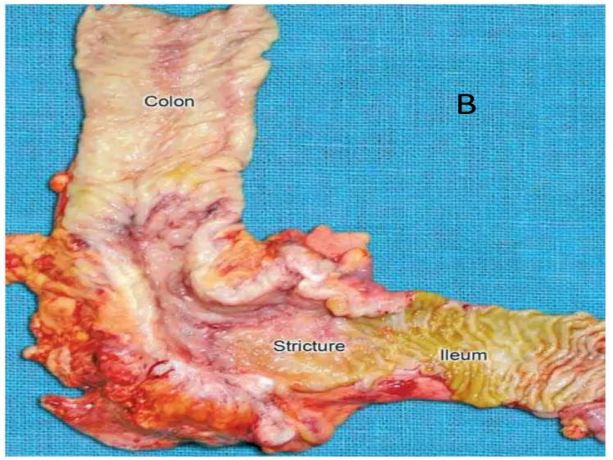

Ileocaecal tuberculosis. (A) Note the multiple transverse undermined ulcers.
(B) Note the ileocaecal tuberculosis with stricture.

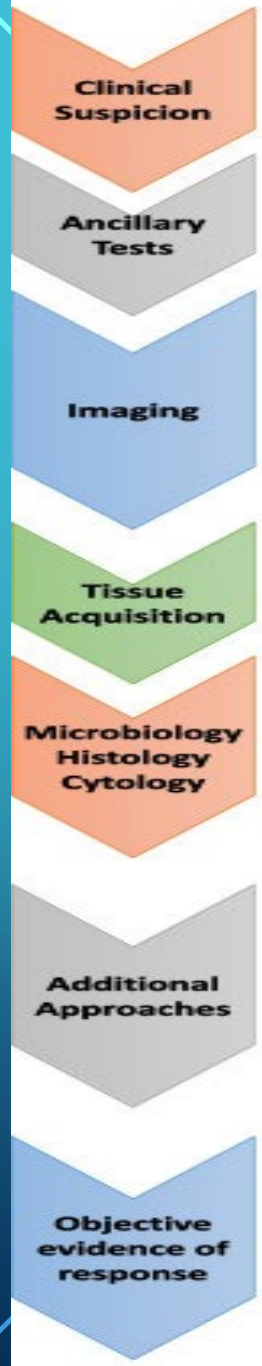

	Peritoneal Tuberculosis	Gastrointestinal Tuberculosis
Clinical Suspicion	• Abdominal distension • Abdominal pain • Fever, loss of appetite, loss of weight • Intestinal obstruction • Lump	• Abdominal pain • Intestinal obstruction • Chronic diarrhea, • Hematochezia • Fever, loss of appetite, loss of weight Lump
Ancillary Tests	**Chest X-ray, Tuberculin skin test, HIV, Blood sugars**	
Imaging	**Ultrasound** • Ascites, omental and peritoneal thickening **Computed Tomography** • Consider if features of pain or obstruction	**Computed Tomography** • Enterography preferable • Bowel thickening, enhancement, lymph nodes, strictures, mesenteric or peritoneal changes • Can guide tissue acquisition, and colonoscopy
Tissue Acquisition	**Blind Paracentesis** **Imaging guided paracentesis or fine needle aspiration cytology/ biopsy**	**Colonoscopy and biopsies** **Imaging guided needle aspiration cytology/ biopsy from lymph nodes**
Microbiology Histology Cytology	• **SAAG:** Usually low • **Cytology:** Lymphocyte predominant • Elevated ascitic adenosine deaminase (>39 U/L) • **Microbiology:** Culture, Nucleic acid amplification tes –Xpert Mtb/Rif	• **Histology:** caseating or confluent, granulomas, ulcer lined by histiocytes • **Microbiology**: Culture, Nucleic acid amplification test–Xpert Mtb/Rif
Additional Approaches	**Diagnosis Uncertain** • May consider additional / newer tests –Multiplex PCR, Xpert Ultra • May consider the use of ancillary supportive tests- CT Chest • Certain tests for discrimination of GITB and CD- Multiparameter model • Laparoscopy for evaluation of peritoneal disease and obtaining additional samples • Consider surgery in luminal disease if severe symptoms or obstruction	
Objective evidence of response	**Diagnostic Antitubercular therapy trial** • Abdominal ultrasound for assessment of peritoneal TB (4-8 weeks)	• Consider colonoscopy at two months for *Early mucosal Response* • Fecal calprotectin: non-invasive monitoring of response
	Lack of response: Consider alternative diagnosis or drug-resistant TB	

	Gastrointestinal Tuberculosis	Peritoneal Tuberculosis
Clinical presentation	Pain dominant Diarrhea dominant	Pain dominant Distension dominant
Morphological	Ulcerative Hypertrophic Stricturing/ Stenotic Combination	Wet – ascitic Dry plastic Fibrotic fixed Cocoon
Diagnosis	Clinical diagnosed (Probable or Possible) Microbiologically diagnosed (Confirmed)	

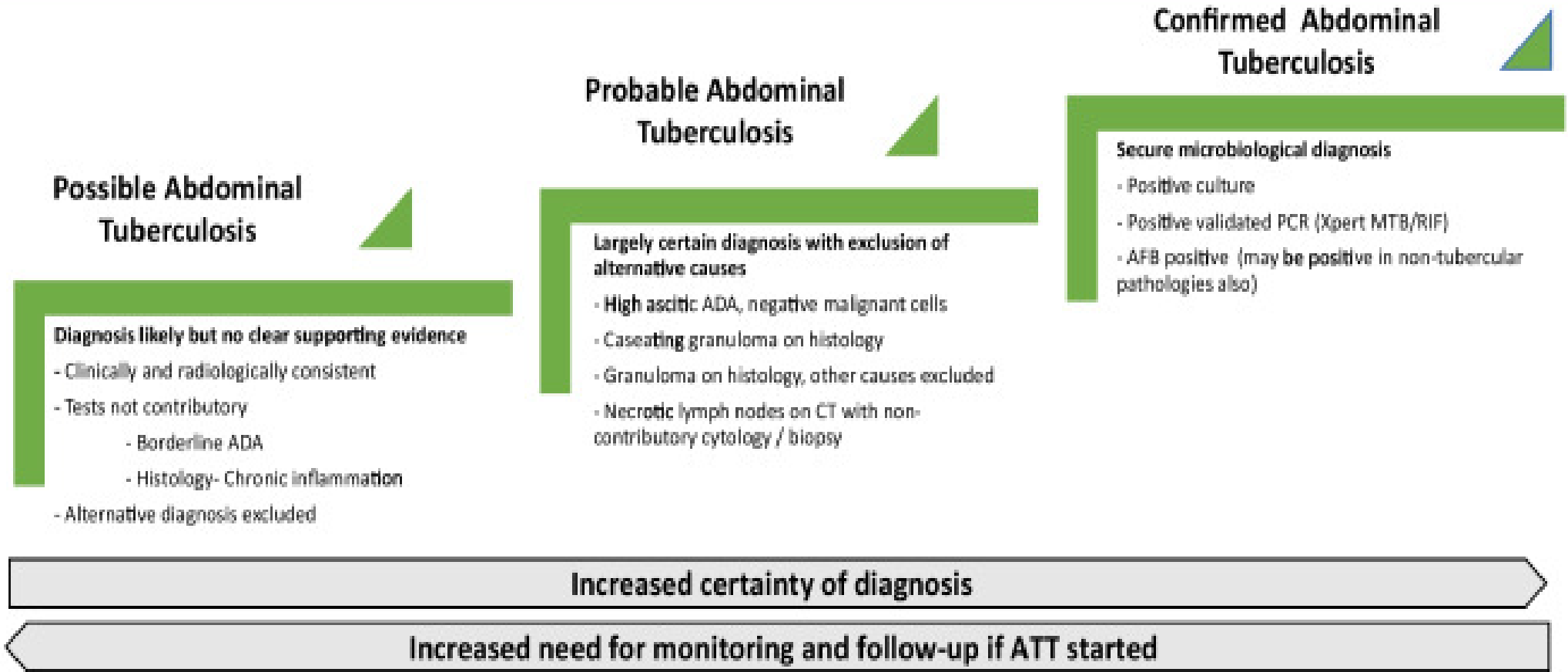


Thanks For Your
Attention